

Idiopathic central precocious puberty: A case report*

BY MARIEL ANNE C. DELA REA, MD AND MARIAN C. DICHOSO, MD, FPOGS

Department of Obstetrics and Gynecology, De La Salle University Medical Center

ABSTRACT

Central precocious puberty is characterized by early pubertal changes, acceleration of growth velocity, and rapid bone maturation. It is a relatively rare disorder, with an incidence rate of about 1 : 5000 – 1 : 10 000 individuals in the general population; it is more frequent in girls than in boys. This is a case of a 7 year-old female complaining of onset of menstruation. Physical examination revealed advanced pubertal changes of Tanner stage 4-5 for breast and stage 3 for pubis. Diagnostic evaluation revealed well developed internal genitalia, markedly elevated LH levels, advanced bone aging and a normal cranial MRI. Based on clinical and diagnostic evaluations, a diagnosis of idiopathic central precocious puberty was made and the patient was started on GnRHa therapy. It is important to initiate therapy early in patients with central precocious puberty so as to prevent compromised adult height and psychosocial embarrassment.

Keywords: Precocious puberty, central precocious puberty, idiopathic central precocious puberty

INTRODUCTION

Physical changes during puberty are controlled by the hypothalamic pituitary gonadal axis which increases its activity before the onset of clinical puberty. The pulsatile secretion of gonadotropin releasing hormone (GnRH) increases and stimulates the pulsatile release of luteinizing hormone (LH) and to a lesser extent follicle stimulating hormone (FSH). This initially occurs at night and then later also during the day with consequential rise in gonadal steroid levels. Signs of pubertal maturation are described by Tanner staging. In girls, breast development is rated from 1 (preadolescent) to 5 (mature), and stage 2 (appearance of the breast bud) marks the onset of pubertal development. Pubic hair stages are rated from 1 (preadolescent, no pubic hair) to 5 (adult), and stage 2 marks the onset of pubic hair development.¹ (Figure 1) The onset of puberty in girls is marked by breast budding (Tanner stage 2) followed by appearance of pubic and axillary hair then maximal growth velocity and finally menarche.²

Precocious puberty is classically defined as the onset of secondary sexual characteristics before the age of 8 years in girls and 9 years in boys. The prevalence of precocious puberty is about 10 times as high in girls as in boys.¹ There are controversies on the age threshold for precocious puberty. Pubertal changes and sexual maturation were noted to occur earlier in African American girls however

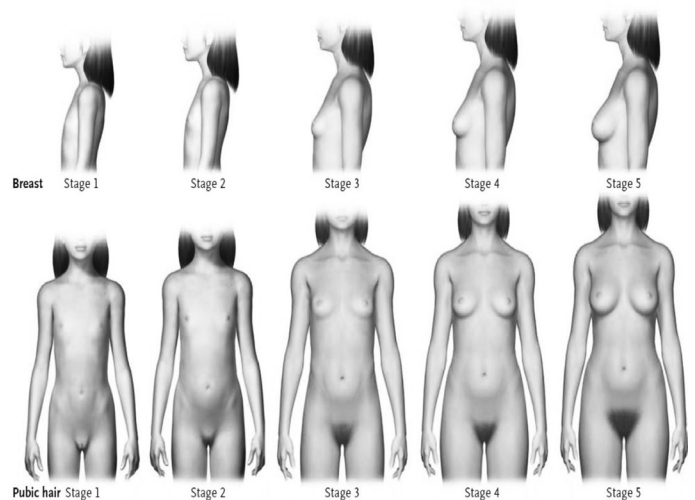


Figure 1. In girls, breast development is rated from 1 (preadolescent) to 5 (mature) and stage 2 (appearance of the breast bud) marks the onset of pubertal development. Pubic hair stages are rated from 1 (preadolescent, no pubic hair) to 5 (adult), and stage 2 marks the onset of pubic hair development.

Source: Jean-Claude Carel, MD and Juliane Leger, MD. Precocious Puberty. *The N Engl J Med* 2008; 358:2366-77

the median age of menarche remains unchanged. New guidelines have been set to help in determining which girls should be evaluated. These guidelines state that Caucasian girls older than 7 years old and African American girls older than 6 years-old, with early breast and/or pubic hair development, should be investigated further in the following condition 1) rapid progression of skeletal maturation (bone age >2 SD of chronological age), 2) new central nervous system (CNS) findings and 3) psychosocial disturbances related to pubertal changes.³

Precocious puberty can be divided into central or

*3rd Place, 2017 Philippine Obstetrical and Gynecological Society (POGS) Interesting Case Paper Contest, April 6, 2017, Citystate Asturias Hotel, Puerto Princesa City, Palawan

gonadotropin dependent precocious puberty wherein there is early activation of pulsatile GnRH secretion. This could be due to hypothalamic lesions but in most cases the cause is idiopathic. Management is medical and often directed to halting the maturation of the hypothalamic-pituitary-gonadal axis. Peripheral or gonadotropin independent precocious puberty results from sex steroid exposure independent of hypothalamic-pituitary-gonadal activation. It may be due to gonadal or adrenal tumors secreting exogenous sex steroids and genetic disorders such as McCune-Albright syndrome. Surgery is indicated for GnRH independent precocious puberty due to gonadal tumors. Peripheral precocious puberty can lead to activation of pulsatile GnRH secretion and to central precocious puberty.¹

CASE REPORT

The index patient is a 7 year-old gravida 0 who presented at the clinic with the chief complaint of vaginal bleeding of 2 days duration, using 4 moderately soaked pads per day with no associated pelvic pain. Breast budding was noted at 5 years of age and pubic hair growth at 6 years-old. The patient was born at around 28 weeks age of gestation and was admitted for 3 months at the neonatal intensive care unit due to prematurity. Her mother was 19 years-old at that time. Her mother's menarche was at 10 years of age. There was no family history of menstrual disorder or congenital malformations. Her parents are separated and she is being raised by her paternal grandparents. The patient has no other siblings. The patient denies any sexual contact. She is right handed.

On physical examination, the index patient had Tanner staging 4 for breast (secondary mound of areola and papilla above the breast), Tanner stage 3 for pubis (labial hair spreads over mons pubis) and note of axillary hair. She weighed 36kg and had a height of 137cm which was at the 94th percentile for girls at her age. She was not pale and had pink palpebral conjunctiva. She had a soft flat abdomen with no palpable mass or tenderness. Pelvic examination revealed normal appearing external genitalia and an intact vaginal canal with passage of minimal amount of menstrual like fluid. As the patient was a virgin, a bimanual rectal examination was done revealing good sphincteric tone, smooth rectovaginal septum and no palpable masses.

Initial working impression was **precocious puberty**.

At the third day of menstruation, transrectal ultrasound showed the presence of normal sized uterus with a length of 3.53 cm and endometrial thickness of 1.15 cm. Both ovaries were normal in size with presence of follicles (Figures 2 & 3). Serum thyroid function tests were within normal range. Both levels of follicle

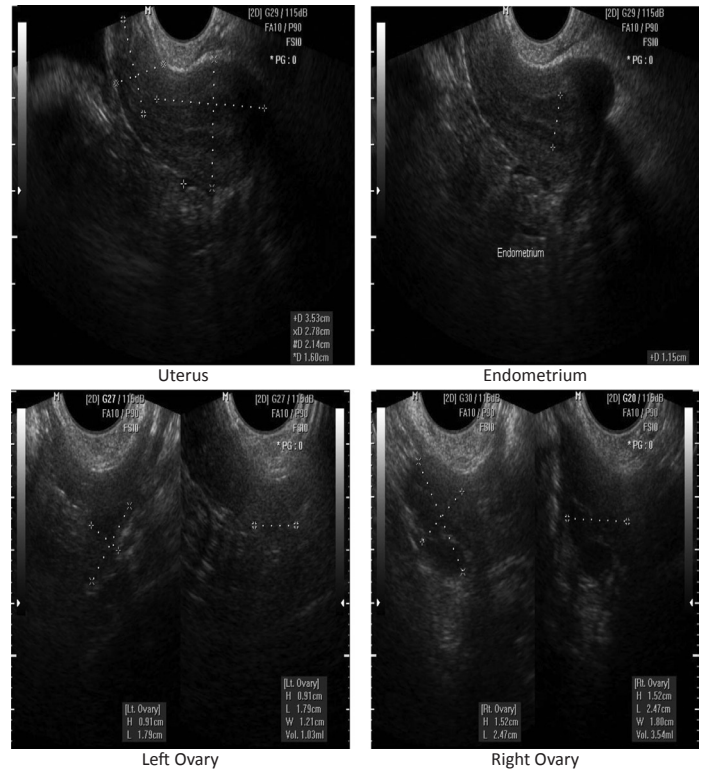


Figure 2

GYNECOLOGY ULTRASOUND REPORT (TRS)

I. Uterine Corpus:	3.53 x 2.97 x 2.78 cm	LxWxH	Retroverted
Description/abnormalities: none			
II. Cervix:	2.14 x 2.38 x 1.60 cm	LxWxH	
Nabothian cyst: None			
Description/abnormalities: None			
III. Endometrium:	1.15 cm	Isoechoic	
Compatible with: Description/abnormalities: None			
IV. Adnexa:	Right ovary	2.47 x 1.80 x 1.52 cm	LxWxH Vol = 3.54 ml
Located: Lateral to the uterus			
Follicle: Present			
Abnormalities noted: none			
Left ovary			
1.79 x 1.21 x 0.91 cm LxWxH Vol = 1.03 ml			
Located: Lateral to the uterus			
Follicle: Present			
Abnormalities noted: none			
V. Color Doppler Study:	N/A		
VI. Others:	No fluid in the posterior cul de sac.		

DIAGNOSIS: Normal sized retroverted uterus with intact endometrium
Normal cervix
Normal ovaries

Remarks: Please correlate clinically.

Figure 3

stimulating hormone (FSH) and luteinizing hormone (LH) were elevated with LH/FSH ratio of 3:1 (Figure 4). Serum androgens levels were within normal range. Her estradiol level was within pubertal range (Figure 5). An x-ray of the patient's non-dominant hand revealed a bone aging of 11 years old using the Greulich-Pyle method (Figures 6 & 7). Cranial magnetic resonance imaging (MRI) with contrast revealed a normal result (Figure 8).

IMMUNOLOGY		
Test Name	Result	Reference Value
FOLLICLE STIMULATING HORMONE		
RESULT	5.31	mIU/ml
MEN : 1.7-12.0 mIU/ml		
WOMEN		
Ovulation	(D-0): 6.3-24 mIU/ml	
Follicular Phase	(D-15 to D-9): 3.9-12 mIU/ml (D-8 to D-2): 2.9-9.0 mIU/ml	
Luteal Phase	(D+3 to +15): 1.5-7.0 mIU/ml	
Menopause	17.0-95.0 mIU/ml	
Prepubertal	Male: Less than 2 IU/L Female: Less than 2 IU/L	
Adult	Follicular: 1-10 IU/L Midcycle: 6-30 IU/L Luteal: 1-8 IU/L	
Postmenopausal	20-100 IU/L	
LUTEINIZING HORMONE		
RESULT :	15.03	mIU/ml
MEN : 1.1-7.0 mIU/ml		
WOMEN		
Ovulation:	(D 0): 9.6-80.0 mIU/ml	
Follicular Phase:	(D-15 to -9): 1.5-8.0 mIU/ml (D-8 to -2): 2.0-8.0 mIU/ml (D+3 to +15): 0.2-6.5 mIU/ml	
Menopause:	8-33.0 mIU/ml	
Prepubertal:	Male: Less than 0.5 IU/L Female: Less than 0.2 IU/L	
Adult:	Male: 1-10 IU/L Female: 1-20 IU/L Midcycle: 25-100 IU/L	

Figure 4

IMMUNOLOGY		
TEST	RESULT	REFERENCE RANGE
ESTRADIOL	44.76 pg/mL	FEMALE: FOLLICULAR PHASE: 12.40-233.00 OVULATION PHASE: 41.00-398.00 LUTEAL PHASE: 22.30-341.00 POST MENOPAUSE: 5.00-138.00

Figure 5

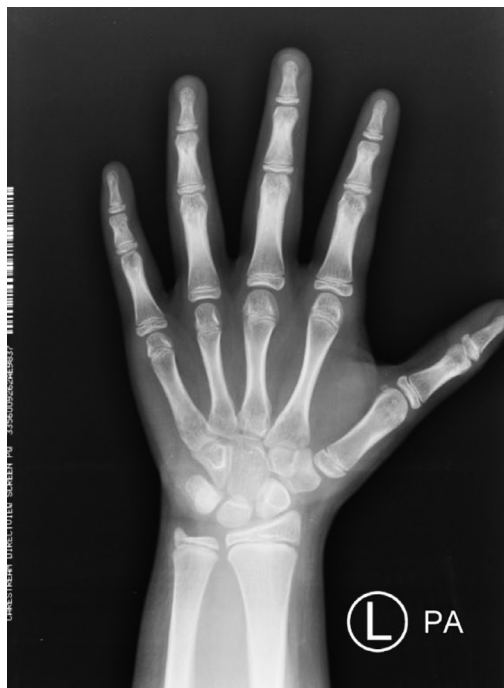

Figure 6

BONE AGING	
INDICATION:	Precocious puberty
COMPARISON:	None
FINDINGS:	
Phalanges:	The female patient is 7 years and 1 month old with a skeletal age of the phalanges compatible with that of an 11 year old. The deviation from the normal for age is: (7 years and 1 month - 11 years)/8.3 = - 5.66 (normal is < 2) which is significant for growth acceleration based on the Greulich-Pyle method.
Metacarpals:	The female patient is 7 years and 1 month old with a skeletal age of the metacarpals compatible with that of an 11 year old. The deviation from the normal for age is: (7 years and 1 month - 11 years)/8.3 = - 5.66 (normal is < 2) which is significant for growth acceleration based on the Greulich-Pyle method.
Carpals:	The female patient is 7 years and 1 month old with a skeletal age of the carpal bones compatible with that of an 11 year old. The deviation from the normal for age is: (7 years and 1 month - 11 years)/8.3 = - 5.66 (normal is < 2) which is significant for growth acceleration based on the Greulich-Pyle method.
Radius and Ulna:	The female patient is 7 years and 1 month old with a skeletal age of the radius and ulna compatible with that of an 11 year old. The deviation from the normal for age is: (7 years and 1 month - 11 years)/8.3 = - 5.66 (normal is < 2) which is significant for growth acceleration based on the Greulich-Pyle method.

Figure 7

Procedure Name:	Procedure ID:
MRI BRAIN WITH CONTRAST	1398744
Comparison: none	
Findings:	
Extra-axial spaces: Normal in size and morphology for the patient's age.	
Intracranial hemorrhage: None	
Ventricular system: Normal in size and morphology for the patient's age.	
Basal cisterns: Normal.	
Cerebral parenchyma: Nonenhancing FLAIR hyperintensity in the right frontal periventricular white matter.	
Midline shift: None.	
Cerebellum: Normal.	
Brainstem: Normal.	
Calvarium: Normal.	
Vascular system: Unremarkable.	
Paranasal sinuses and mastoid air cells: Minimal hyperintensities are seen in both maxillary sinuses. The rest of the paranasal sinuses and both mastoid air cells are clear.	
Visualized orbits: Normal.	
Visualized upper cervical spine: Normal.	
Sella: The pituitary gland is normal in size for patient's age. No definite abnormal hypoenhancing nodule appreciated. The pituitary stalk is midline.	
Skull base: Normal.	
Marrow: Normal.	
Others: The adenoids are hypertrophied.	
IMPRESSION:	
Normal size of the pituitary gland with no definite nodule seen	
Nonenhancing FLAIR hyperintensity in the right frontal periventricular white matter, which is nonspecific and may be seen in cases of chronic migraine.	
Mild inflammatory disease, both maxillary sinuses.	
Adenoid hypertrophy.	

Figure 8

At this time, the impression was idiopathic central precocious puberty.

After the initial cycle of menstruation which lasted for 5 days, the patient had another 2 cycles of menstruation occurring at 35-52 days interval, lasting for 5 days. After her third cycle and prior to initiation of therapy, the index patient weighed 39 kg and had a height of 139cm (height

increase of 2 cm in 3 months). Tanner staging of the breast had progressed to stage 5 while the pubis remained at stage 3 (Figures 9, 10 & 11).

The patient was started on gonadotropin releasing hormone agonist (GnRHa), leuproride acetate, 3.75 mg given at 28 days interval. Psychosocial counseling was also offered to the patient and her family.

CASE DISCUSSION

This is a case of a 7 year-old complaining of onset of menstruation. Physical examination revealed advanced pubertal changes of Tanner stage 4-5 for breast and stage 3 for pubis. Diagnostic evaluation revealed well developed internal genitalia, markedly elevated LH levels, advanced bone aging (>2SD of chronological age) and normal cranial MRI. Based on clinical and diagnostic evaluation, a diagnosis of idiopathic central precocious puberty was made and the patient was started on GnRHa therapy.

Central precocious puberty is characterized by hypothalamic-pituitary-gonadal axis activation leading to progressive pubertal development, acceleration of growth velocity, and rapid bone maturation that often results in reduced adult height. It is a relatively rare disorder, with an incidence rate of about 1 : 5000 – 1 : 10 000 individuals in the general population; it is more frequent in girls than in boys, with the female : male ratio estimated to be between 3 : 1 and 23 : 1³. It is more common than peripheral precocious puberty and accounts for up to 90% of published cases⁴. Idiopathic central precocious puberty is sometimes familial and occurs more frequently than organic central precocious puberty. It is more common in girls (74%) than in boys (60%).³ The onset of organic central precocious puberty is earlier usually before the age of 3 in girls.³ On the other hand, organic central precocious puberty is more common in boys than girls (40-90% vs. 8-33%).

A search for local data revealed a total of 11 reported cases of precocious puberty, only 2 of which were central precocious puberty - a case of hypothalamic hamartoma and a case of 3 year-old with idiopathic central precocious puberty.⁵⁻¹⁵

Many environmental, endocrine and genetic factors affect the onset of puberty: 1) race 2) early maternal menarche 3) low birth weight 4) excessive weight gain in infancy and early childhood 5) after international adoption 6) when no father is present in the household¹. However, these factors are associated with only a fraction of causes of early puberty and are not considered as main etiology of the disease. *Factors noted in the index patient include prematurity at birth (low birth weight) and the absence of a father in the household.*

Examination of a child with precocious puberty should

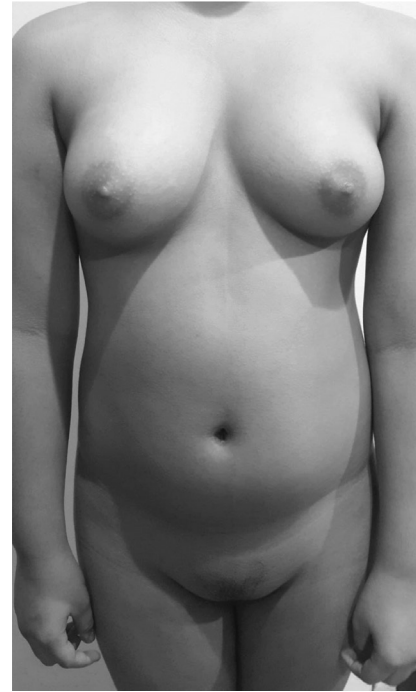

Figure 9

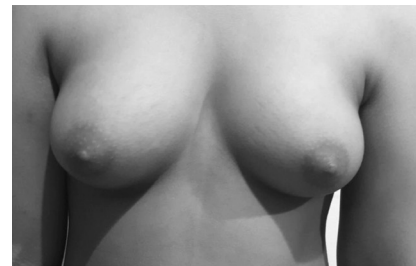


Figure 10

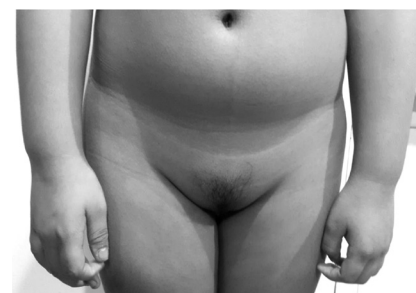

Figure 11

start with accurate family and personal medical history, physical examination and pubertal staging. A complete personal history is necessary, including the age at onset of puberty and progression of pubertal manifestations which is often more rapid in precocious puberty. There also should be note of any evidence suggesting possible central nervous system dysfunction, such as headache, increased head circumference, visual disturbances, or seizures. Family history should include the age at onset of puberty in parents and siblings. Growth should be evaluated since progressive precocious puberty is associated with a high growth velocity. The stage of pubertal development should be classified as described by Tanner. Careful assessment is needed in obese girls to avoid overestimating breast development. The development of pubic hair results from the effects of androgens, which may be produced by functioning ovaries in central precocious puberty. In girls, pubic hair in the absence of breast development is suggestive of adrenal disorders, premature pubarche, or exposure to androgens.¹ It would be helpful to assess signs of specific causes of precocious puberty, such as hyperpigmented skin lesions suggesting neurofibromatosis or the McCune-Albright syndrome.

Diagnosis of central precocious puberty is based on the signs of activation of the hypothalamic-pituitary-gonadal axis in girls younger than 8 years-old. This includes breast tanner stage of >1, uterine volume (longitudinal diameter >3.5cm), increased height velocity, bone age >2 SD above chronological age, menstrual bleeding and increased basal or stimulated LH³. The course of precocious puberty is considered progressive or accelerated when tanner stage 3 is reached before 10 years of age. *In the index patient, breast budding was noted at 5 years-old and pubic hair growth at 6 years of age. Upon initial examination tanner staging was 4 and 3 for breast and pubis, respectively but there was progression to tanner stage 5 for breast after 2 months indicating possible rapid progression. Further diagnostic tests revealed uterine length of 3.53 cm, markedly elevated LH levels and increased height velocity, all of which are associated with progressive precocious puberty.*

It is necessary to establish the degree of skeletal maturation. In precocious puberty, skeletal maturation and statural growth are accelerated (the former more than the latter), so the child is mature more than they grow. The child with precocious puberty is deprived, according to the age of onset, of a certain period of normal pre-pubertal growth and thus final adult height is shorter than the target height. A reference atlas such as the one by Greulich and Pyle can be used to evaluate the effect of sex steroids on epiphyseal maturation; the bone age of patients with precocious puberty is consistently greater than their chronologic age (> 2 SD above chronological age). *In the index patient, bone aging of the non dominant*

hand revealed a skeletal age of 11 years-old, much greater than her chronological age.

The gold standard for evaluation of precocious puberty is the measurement of gonadotropins at 0, 15, 30, 45, 60 and 90 minutes after stimulation by intravenous GnRH (which is unavailable in many countries including the United States and the Philippines).³ Early activation of hypothalamic-pituitary-gonadotropin axis is demonstrated by maximal luteinizing hormone level after GnRH stimulation. In an attempt to simplify the GnRH test, a single determination of basal LH of > 0.3 IU/L or an LH peak \geq 5 IU/L at 30 to 60 minutes after GnRH stimulation suggest progressive central precocious puberty.^{3,23} Onset of puberty starts with increased LH secretion compared to FSH and so an increased LH/FSH ratio may be indicative of central precocious puberty. *In the absence of intravenous GnRH, basal LH and FSH levels were obtained from the index patient on her 3rd day of menstruation. Basal LH level was at 15.03mIU/ml and her LH/FSH ratio was 3:1. Both results established the diagnosis of central precocious puberty. (IU/L=mIU/ml)*

Gonadotropin levels in children younger than 3 years old should be interpreted with caution, because gonadotropin levels are normally high in this age group. Random measurements of follicle-stimulating hormone are not useful, since they vary little throughout pubertal development.¹

In all cases of central precocious puberty, MRI of the brain should be performed to rule out any hypothalamic lesion. The prevalence of such lesions is higher in boys (40 to 90%) than in girls (8 to 33%) presenting with precocious puberty and is much lower when puberty starts after the age of 6 years in girls (<2%).¹ The most frequent CNS lesion associated with precocious puberty is hypothalamic hamartoma. Small and pedunculated hypothalamic hamartomas are often associated with central precocious puberty while large and sessile ones are associated with seizures. The younger the child (<4 years-old), the higher the possibility of a CNS lesion in central precocious puberty. *Cranial MRI of the index patient revealed normal result.*

In at least 50% of cases of precocious puberty, pubertal manifestations will regress or stop progressing, and no treatment is necessary.¹ The decision to treat depends on the child's age, the rate of pubertal progression and height velocity. Pubertal progression is considered slow if there is no choice in Tanner staging of breast and pubis during a 6 month observation. Height velocity is accelerated if it is more than 6 cm per year. *In a 3 month observation of the index patient, tanner stage for breast progressed from 4 to 5 and height was increased by 2 cm.* For cases in which precocious puberty progresses, concerns include early menarche in girls and short adult stature due to early epiphyseal fusion and adverse psychosocial outcomes.¹

Thus, the two main reasons for treating patients with idiopathic central precocious puberty is to improve psychosocial well being and to prevent compromised adult height.

GnRH agonists are the gold standard in the management of progressive central precocious puberty. They provide continuous stimulation of the pituitary gonadotrophs, leading to desensitization and decrease in the release of LH and, to a lesser extent, FSH. This leads to decreased sex steroid production. Factors affecting height gains include baseline bone age (markedly advanced bone age associated with shorter adult height) and duration of treatment (onset of treatment at a younger age and a longer duration of treatment associated with greater height gain). Normal adult height can be achieved if treatment is started before bone maturation is too advanced and if gonadal suppression is maintained for several years.

Most common GnRH agonist used for the treatment of central precocious puberty is the monthly 3.75 mg intramuscular injection. Dose can be increased depending on the response of the patient to the therapy. Other forms/dosage of GnRH agonist have also been used for central precocious puberty-3-month depot formulations (11.25 and 30 mg) and the once-yearly histrelin subcutaneous implants. Although these formulations have not been studied as extensively as the 1 month depot leuprolide acetate formulation, they have proven to be as effective and with better compliance due to the less frequency of administration.^{16,17,18} Higher LH and FSH levels were seen with the 11.25 mg 3-month leuprolide acetate dose but no differences in final growth velocity and bone age progression was noted. However, during monitoring of treatment higher dosing was required in some circumstances.¹⁸ *The index patient was offered both the 1 month (3.75 mg) and 3 month (11.25 mg) dosing but her family opted to start the monthly leuprolide acetate administration.*

Several methods have been proposed in monitoring pubertal suppression during GnRH agonist therapy. Traditionally, LH level of < 2 IU/L obtained 30-60 minutes after GnRH stimulation indicate adequate pubertal suppression.^{3,19,20} Other methods have been investigated and appear more applicable to the Philippine setting since GnRH is unavailable. A study done by Zung et al compared basal, post GnRH agonist and first voided urinary LH as alternative methods to GnRH stimulation test in assessing pubertal suppression during treatment.²¹ The study concluded LH levels obtained 24 hours after the GnRH agonist injection was accurate enough to determine adequate pubertal suppression. Basal LH, urinary LH and estradiol levels did not correlate well with the degree of suppression.²¹ In another study, LH level \leq 2.5 mIU/ml

obtained 90 minutes after GnRH agonist administration indicates adequate suppression with a sensitivity of 100% and specificity of 88%.²² A study by Brito et al indicated LH level of < 6.6 IU/L obtained 2 hours after GnRH agonist administration was consistent with adequate pubertal suppression.²⁰ *Repeat LH level was determined in the index patient 90 minutes after her 3rd monthly GnRH (3.75 mg) administration. The result was 1.83 mIU/ml (basal LH level was at 15.03mIU/ml).*

Aside from laboratory evaluation, the patient must be monitored clinically to assess gonadal suppression. The patient's BMI, tanner staging and growth velocity should be evaluated every 3-6 months. Bone age should be evaluated every 6 months. Successful therapy would indicate arrest or regression of tanner staging and bone aging nearing chronological age.²² *At the time of submission of this paper, the index patient had completed 6 months of treatment. Her height remained unchanged after her third GnRH injection at 141 cm. Tanner staging of the breast regressed to tanner stage 3 after the fourth GnRH injection and to tanner stage 2 after the sixth injection. There was no progression of tanner staging for her pubis.*

The optimal time to stop treatment has not been established, but most studies suggest that treatment beyond the age of 11 years is not associated with significant further height gain.¹ Pubertal manifestations reappear within months after discontinuing GnRH agonist treatment. Follow up 6 months after completion of treatment is recommended to ensure puberty subsequently progresses normally.

For cases in which precocious puberty is caused by a central lesion (e.g., a mass or malformation), management of the lesion generally has no effect on the course of pubertal progression. Initial management of hypothalamic hamartomas include the use of GnRH agonist since significant risk is associated with surgery and removal of the lesion does not guarantee pubertal regression.²³

No adverse effects on reproductive development or fertility have been found to be associated with GnRH agonist therapy. There was reversibility of hypothalamic pituitary ovarian axis suppression after cessation of GnRH agonist treatment.²⁴ In a prospective study involving long term follow-up and adult callback after completion of treatment with 1 month leuprolide acetate depot, all patients achieved pubertal hormonal response within 1 year after cessation of treatment and no impairment of reproductive function was observed in adulthood.²⁵

In contrast to adults, hypoestrogenic state induced by the long term use of GnRH agonist in early pubertal stage does not result in deterioration of the bone mineral density.²⁶ Pituitary-ovarian suppression by GnRH agonist does not reverse or prevent bone mass acquisition.²⁷

The negative psychosocial implications of early sexual development should not be underestimated. Precocious pubertal changes have been associated with adverse psychosocial outcomes and psychological evaluation may be useful. However, there is limited available data that are specific to patients with precocious puberty. A study done by Baumann et al in 2001 showed that patients with history of precocious puberty had behavioral problems including neuroticism and feelings of insecurity.²⁸ Patients suffering from precocious puberty are at risk for depression, anxiety, difficult socialization, early sexual activity at a young age and sleep disturbances.

CONCLUSION

The onset of precocious puberty has important physical and psychological consequences for affected children and induces anxiety in their families. However, not all girls with early signs of puberty require treatment. It is necessary to make a rapid, correct diagnosis as well as to form a judgment concerning the progression of the condition based on a combination of clinical signs and diagnostic evaluation thus providing the appropriate treatment to prevent psychosocial embarrassment and poor height prognosis in these patients. ■

REFERENCES

- Jean-Claude Carel, MD and Juliane Leger, MD. Precocious Puberty. *The N Engl J Med*. 2008; 358:2366-77.
- Lobo R, Lentz G, Gershenson D and Katz V: Comprehensive Gynecology, 6th ed. USA: Elsevier Mosby, 2012.
- Franco Antoniazzi and Giorgio Zamboni. Central Precocious Puberty Current Treatment Options. *Pediatr Drugs*. 2004; 6 (4):211-231.
- Martin Chalumeau, MD, Wassim Chemaitilly, MD, Christine Trivin PhD, Luis Adan, MD, Gerard Breart, MD and Raja Brauner, MD. Central Precocious Puberty in Girls: An Evidence-Based Diagnosis Tree to Predict Central Nervous System Abnormalities. *Pediatrics* Vol. 109 No. 1 January 2002.
- Christine Marie Caligagan-Bucad. Precocious Puberty: A Case Report. *Philippine Scientific Journal*. 2002; 35(2):44-58.
- Ouano MML, Gamuac RC, Ortiz MH. Isosexual Precocious Puberty and Gelastic Seizure with Hypothalamic Mass – Case Report and Review of Literature. *The PCMC Journal*. 1992; 0.
- Mercado-Asis LB, Gallardo LT, Reyes-Rivera CT, Araza LA. McCune-Albright Syndrome. *Congress Programme and Book of Abstracts*. 1996; 0.
- Torres, JRS. Precocious Puberty in a Child with an Ovarian Sex Cord Tumor. *Philippine Journal of Obstetrics and Gynecology*. 1999; 0.
- Madona Victoria Calderon-Domingo, Ina S. Irabon, Pure Sertoli Cell Tumor of the Ovary, A Rare Cause of Isosexual Pseudoprecocious Puberty in a Two Year Old Girl. *Philippine Journal of Reproductive Endocrinology and Infertility*. January 2009; Vol. 6 (2): p. 68-79.
- Carmela Lapitan, Liemer R Miranda. Precocious Puberty as the Presenting Feature of Leydig Cell Tumor of the Testis. PCHRDP051089.
- Enrico Gil C. Oblepias, Margaret Joyce A. Cristi-Limson. A Rare Case of Isosexual Pseudoprecocious Puberty in a Patient with Mixed Germ Cell Malignancy of the Ovary with Endodermal Sinus Tumor and Dysgerminoma. *Philippine Journal of Obstetrics and Gynecology*. October 2012; Vol. 36 (4): p. 166-174.
- Helen Valenzona Madamba, Ma. Cristina Palaez-Crisolongo. An Ovarian Sex Cord Tumor with Annular Tubules. *Philippine Journal of Obstetrics and Gynecology*. July 2012; Vol. 36 (3): p. 144-148.
- Arlene Tiong-Samonte. Precocious puberty. *Philippine Journal of Pediatrics*; Vol. 36 (1) : p. 65-77.
- Cyriel Anthony I. Tingne, Agnes L. Soriano-Estrella. Juvenile Granulosa Cell Tumor of the Ovary Presenting as Isosexual Precocious Puberty: A Case Report. *Philippine Journal of Obstetrics and Gynecology*. July 2015; Vol. 39 (3): p. 28-33.
- Manish Gutch, Sukriti Kumar, Keshav Kumar Gupta, Abhinav Kumar Gupta, Syed Mohd Razi. McCune-Albright Syndrome with Hypophosphatemic Rickets. *Journal of the ASEAN Federation of Endocrine Societies*. May 2015; Vol. 30 (1) : p. 40-43.
- Lee PA, Klein K, Mauras N, Neely EK, Bloch CA, Larsen L, Mattia-Goldberg C, Chwalisz K. Efficacy and safety of leuprolide acetate 3-month depot 11.25 milligrams or 30 milligrams for the treatment of central precocious puberty. *J Clin Endocrinol Metab*. 2012 May; 97(5):1572-80. *Epub*. 2012; Feb 16.
- Silverman LA, Neely EK, Kletter GB, Lewis K, Chitra S, Terleckyj O, Eugster EA. Long-Term Continuous Suppression With Once-Yearly Histrelin Subcutaneous Implants for the Treatment of Central Precocious Puberty: A Final Report of a Phase 3 Multicenter Trial. *J Clin Endocrinol Metab*. 2015 Jun; 100(6):2354-63. *Epub*. 2015 Mar 24.
- Fuld K, Chi C, Neely EK. A randomized trial of 1- and 3-month depot leuprolide doses in the treatment of central precocious puberty. *J Pediatr*. 2011; 159(6):982.
- Nurgun Kandemir, Huseyin Demirbilek, Zeynep Alev Ozon, Nazli Gonc, Ayfer Aliasifoglu. GnRH Stimulation Test in Precocious Puberty: Single Sample is Adequate for Diagnosis and Dose Adjustment. *J Clin Res Ped Endo*. 2011; 3(1):12-17.
- Vinicius N. Brito, Ana C Latronico, Ivo J.P. Arnhold and Bernice B. Mendonca. A Single Luteinizing Hormone Determination 2 Hours After Depot Leuprolide is Useful for Therapy Monitoring of Gonadotropin-Dependent Precocious Puberty in Girls. *The Journal of Clinical Endocrinology & Metabolism*. November 2009; 89(9):4338-4342.

REFERENCES

21. Amnon, Zung, Ella Burundukov, Mira Ulman, Tamar Glaser and Zvi Zadik. Monitoring Gonadotropin-Releasing Hormone Analogue (GnRHa) Treatment in Girls With Central Precocious Puberty: A Comparison of Four Methods. *Pediatr Endocr Met.* 2015; 28(7-8):885-893.
22. Huseyin Demirbilek, Ayfer Alikasifoglu, Nazli E. Gonc, Alev Ozon and Nurgun Kandemir. Assessment of Gonadotrophin suppression in Girls Treated with GnRH Analogue for Central Precocious Puberty; Validity of Single Luteinizing Hormone Measurement After Leuprolide Acetate Injection. *Clinical Endocrinology.* 2012; 76, 126-130.
23. Stewart L, Steinbok P, Daaboul J. Role of surgical resection in the treatment of hypothalamic hamartomas causing precocious puberty. Report of six cases. *Journal Of Neurosurgery [J Neurosurg]*. 1998 Feb; Vol. 88 (2), pp. 340-5.
24. Thornton P, Silverman LA, Geffner ME, Neely EK, Gould E, Danoff TM. Review of outcomes after cessation of gonadotropin-releasing hormone agonist treatment of girls with precocious puberty. *Pediatric Endocrinology Reviews: PER [Pediatr Endocrinol Rev]*. 2014 Mar; Vol. 11 (3), pp. 306-17.
25. E. Kirk Neely, Peter A. Lee, Clifford A. Bloch, Lois Larsen, Di Yang, Cynthia Mattia-Goldberg, Kristof Chwalisz. Leuprolide Acetate 1-Month Depot for Central Precocious Puberty: *Hormonal Suppression and Recovery International Journal of Pediatric Endocrinology.* Volume 2010, p. 1-9.
26. Hong K. Park, Hae S. Lee, Jung H. Ko, Il T. Hwang, Jung S. Lim and Jin S. Hwang. The effect of gonadotrophin-releasing hormone agonist treatment over 3 years on bone mineral density and body composition in girls with central precocious puberty. *Clinical Endocrinology.* 2012; 77:743-748.
27. Jung Hee Ko, Hyo Sung Lee, Jung Sub Lim, Shin Mi Kim, Jin Soon Hwuang. Changes in Bone Mineral Density and Body Composition in Children with Central Precocious Puberty and Early Puberty Before and After One Year of Treatment with GnRH Agonist. *Horm Res Paediatr.* 2011; 75:174-179.
28. D.A. Bauann, M.A. Landolt, R. Wetterwald, J.M. Dubuis, P.C. Sizonenko, E.A. Werder. Psychological Evaluation of Young Women After Medical Treatment for Central Precocious Puberty. *Horm Res.* 2001; 56:45-50.
29. Gonul Catli, Pinar Erdem, Ahmet Anik, Ayhan Abaci, Ece Bober. Clinical and Laboratory Findings in the Differential Diagnosis of Central Precocious Puberty and Premature Thelarche. *Turk Pediatri Arsivi.* 2015; 50:20-6.
30. John S. Fuqua. Treatment and Outcomes of Precocious Puberty: An Update. *J Clin Endocrinol Metab.* June 2013; 98(6):2198-2207.
31. Melinda Chen and Erica A. Eugster. Central Precocious Puberty: Update on Diagnosis and Treatment. *Pediatr Drugs.* 2015; 17:273-281.
32. P.S.N. Menon, M. Vijayakumar. Precocious Puberty – Perspectives on Diagnosis and Management. *Indian J Pediatr.* January 2014; 81(1):76-83.
33. Wassim Chemaitilly, Christine Trivin, Luis Adan, Valerie Gall, Christian Sainte-Rose and Raja Brauner. Central Precocious Puberty: Clinical and Laboratory Features. *Clinical Endocrinology.* 2011; 54:289-29.